Ann. For. Res. 65(1): 1743-1751, 2022
ISSN: 18448135, 20652445

ANNALS OF FOREST RESEARCH
https://www.e-afr.org/

A STUDY ON EFFECTIVENESS OF TALONAVICULAR JOINT MOBILISATION AND FIRST METATARSOPHALANGEAL JOINT MOBILISATION ON PES CAVUS SUBJECTS WITH PLANTAR FASCIITIS

Ms.Hepzibah Rubella D
MPT (Orthopaedics), Research Scholar, SOPT, VISTAS, Chennai
Email ID: hepziphysio@gmail.com

DR.M.S.Sundaram
MPT (Sports), PhD, Professor, SOPT, VISTAS, Chennai

DR. P. Senthil Selvam
MPT (Orthopaedics), PhD, Professor & HOD, SOPT, VISTAS

ABSTRACT
BACKGROUND: Idiopathic pes cavus is a structural foot deformity characterized by rigid high and medial longitudinal arch which frequently occurs due to muscle imbalance. About 60% of the deformed individuals report with persistent foot pain due to high plantar pressure leading to important functional limitations.
AIM & OBJECTIVE: To find out the effectiveness of mobilization on talonavicular joint and first metatarsophalangeal joint mobilization on pes cavus subjects with plantar fasciitis, thereby reducing their functional disability.
PROCEDURE: An experimental study was conducted on subjects with pes cavus foot between 17-38 years of age. Total 28 subjects were divided equally into two groups 14 each. Group A was given talonavicular joint mobilization and Group B was given first metatarsophalangeal joint mobilization, along with TENS and plantar fascia stretch in common. Pre and post test measures were done using NPRS for pain, Goniometer for reduced dorsiflexion ROM, Musculoskeletal Ultrasonogram (Fascia thickness) and FAAM Questionnaire for ADL.
RESULT: Statistical analysis was done using the paired t test(intra group) and unpaired t test (inter group). Both groups showed a significant improvement ($p<0.05$) in NPRS, Goniometer, faam questionnaire, whereas; group B (first MTP joint) showed significant improvement in plantar fascia with reduction in thickness using Musculoskeletal ultrasonogram.
CONCLUSION: It is concluded that there was a significant improvement in mobilizing the first MTP joint on pes cavus subjects with plantar fasciitis.
KEYWORDS: high arch, Plantar Fasciitis, FAAM questionnaire, Musculoskeletal Ultrasonogram.

I. INTRODUCTION:

Pes cavus, often known as the cavus foot, is a structural foot deformity that is frequently caused by an unbalanced muscle structure with a high and inflexible medial longitudinal arch. High

© ICAS 2022

plantar pressures and a noticeably elevated load under the metatarsal area are likely to cause persistent foot discomfort in about 60% of people with cavus feet. Therefore, foot pain brought on by cavus foot may result in significant functional limits. (1)

In healthy working people, the prevalence of Pes cavus is 50.8%. The subtalar joint often moves in the supination direction. The talonavicular joint is connected to talar abduction and dorsiflexion, the calcaneus is notably inverted, and the medial longitudinal arch height is conspicuously high. A foot that appears to be locked in this position is frequently referred to as "supinated," pes cavus, or high arched foot.

There are two possible causes of pes cavus: neurological or idiopathic. Because the mechanism of foot discomfort associated with pes cavus is poorly understood, it is particularly challenging to effectively manage these people. A common reason why people seek medical attention is idiopathic pes cavus. (2) In cases of severe deformity, generalised therapies included modified footwear and osteotomies.

Reduce the forefoot's plantarflexion and relax the plantar fascia are the goals of therapeutic care, whether conservative or surgical. To optimise the distribution of plantar pressures, offer comfort and stability during walking, and reduce tiredness in the lower extremities, orthoses, often custom-made insoles, are the most widely used nonoperative technique in the clinical context.

In order to stop the advancement of cavus foot and associated impairment, a variety of footwear styles as well as intramuscular botulinum toxin injections have been employed. Reactivating the proprioceptive system, particularly the ankle's mechanoreceptors, was one effect of the osteoarticular structures being mobilised to a reduced extent. As a result of these mechanoreceptors being stimulated, there may be an increase in afferent input from the talocrural and subtalar joints and surrounding tissues, which could reduce discomfort and improve balance. (3)

"Short term standing in High heels shortens the transverse arch and tightens the space between the metatarsal heads and the plantar surface of the foot," Hala Zeiden's study from 2020 concluded. According to the findings of this study, wearing high heels alters the transverse arch's shape and height.

Hence, this study was intended to analyze the effects of mobilization in plantar fasciitis subjects with Pes Cavus.

II. MATERIALS & METHODS:

This is an experimental study with a practical sampling of 28 people, 14 in each of the two groups. The informed consent was made available for participants to sign and then participate voluntarily. An intervention period of two weeks was followed by a pretest in this study. The Foot and Ankle Ability Measure (FAAM) questionnaire for functional activities, the Goniometer measurement for dorsiflexion range of motion, the Musculoskeletal Ultrasonogram for measuring plantar fascia thickness, and the NPRS for measuring pain intensity were the outcome measures used in this study.

© ICAS 2022

Inclusion criteria: both gender, Affected Dorsiflexion ROM (25 degrees), Musculoskeletal Ultrasonogram: plantar fascia >4 mm, Pain in the plantar area of the foot ranging from 2 to 7 in NPRS. (2)

Exclusion criteria: Vestibular disorders, eg: vertigo, dizziness, Neurological disorders, eg: entrapment, peripheral neuropathies, Metabolic disorders, eg: diabetic, Vascular disorder, eg: stroke, DVT, Psychatric problems, eg: attention deficit, obsessive compulsive disorder, Uncorrected vision disorders, History of trauma in and around ankle & foot for past 6 months. (3)

III. PROCEDURE

Active intervention was given for 12 sessions for duration of 2 week (6days/week) with 3sets-30second sets and with a 30second interval between each set.

o Talonavicular – anterior and posterior glide in supine lying.

o First MTP – anterior and posterior glide in supine lying .

TENS were given to both groups to minimise pain and maintain flexibility followed by mobilisation with 50Hz frequency, one electrode placed over retrocapital metatarsal area and the other over the heel. For 8-10mins (1)

Pre and post test measures were taken before and after intervention for statistical analysis.

Fig1 : Talonavicular joint mobilisation

Fig 2: First MTP joint mobilisation

© ICAS 2022


Fig 3: TENS application

IV. STATISTICAL ANALYSIS

Statistical analysis was done using the paired t test(intra group) and unpaired t test (inter group). Both groups showed a significant improvement ($p<0.001$) in NPRS, Goniometer, faam questionnaire. Group B (first MTP joint) showed significant improvement in reduction of pain , improving ROM and ADL whereas, talonavicular joint mobilisation (Group A) showed that there is reduction in plantar fascia thickness when compared with Group B using Musculoskeletal ultrasonogram.

ANALYSIS WITHIN THE GROUP
GROUP A - TALONAVICULAR MOBILIZATION

OUTCOME	MEAN VALUE		MEAN DIFF	STANDARD DEVIATION		t VALUE	p VALUE
	PRE	POST		PRE	POST		
NPRS	5.7	4.4	1.3	1.1	1.6	2.49	0.02
ROM	17.5	19.3	1.8	3.8	3.8	1.36	0.22
USG	4.1	3.3	0.8	0.5	0.7	3.28	0.003
FAAM	44.3	59.3	15	17.9	16.7	2.39	0.03

© ICAS 2022

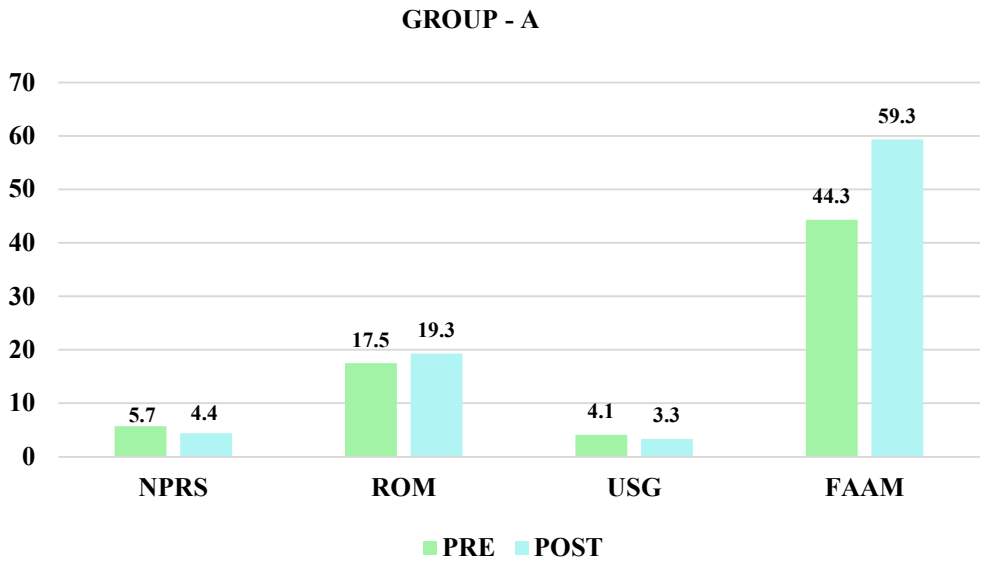

ANALYSIS WITHIN THE GROUP
GROUP B - 1ST MTP MOBILIZATION

OUTCOME	MEAN VALUE		MEAN DIFF	STANDARD DEVIATION		t VALUE	p VALUE
	PRE	POST		PRE	POST		
NPRS	5.9	3.8	2.1	0.9	1.4	4.73	0.0001
ROM	18.3	21.1	2.8	2.9	2.2	2.95	0.008
USG	3.9	3.5	0.4	0.7	0.6	1.52	0.14
FAAM	40.4	62.1	21.7	14.1	14.2	4.17	0.0004

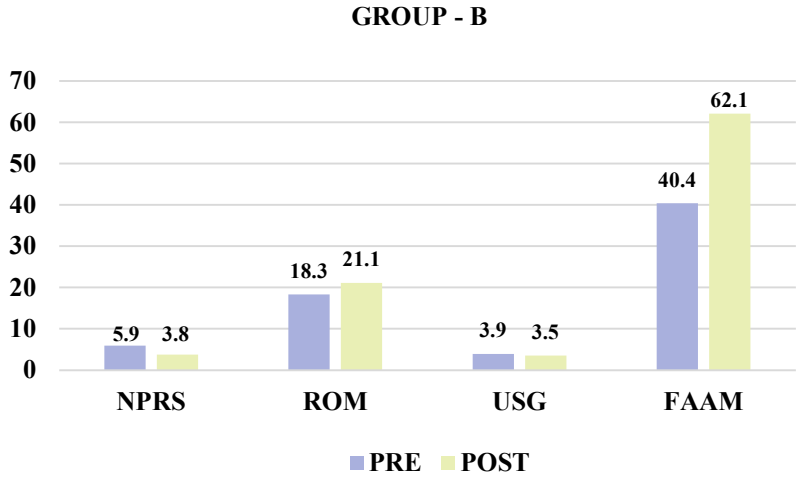

© ICAS 2022

ANALYSIS BETWEEN THE GROUP
GROUP A & GROUP B

OUTCOME	GROUP A			GROUP B			p VALUE
	PRE	POST	MEAN DIFF	PRE	POST	MEAN DIFF	
NPRS	5.7	4.4	1.3	5.9	3.8	2.1	0.26
ROM	17.5	19.3	1.8	18.3	21.1	2.8	0.14
USG	4.1	3.3	0.8	3.9	3.5	0.4	0.44
FAAM	44.3	59.3	15	4.04	62.1	21.7	0.63

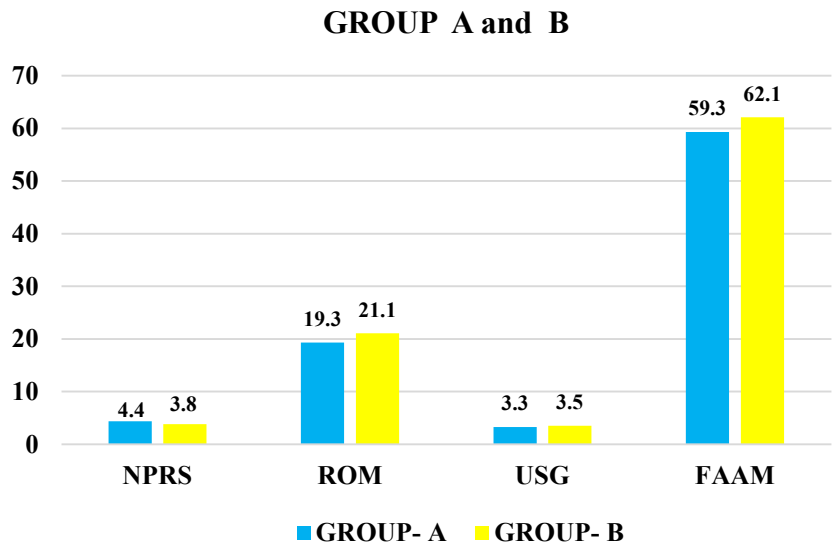

V. RESULTS

Table 1:

The mean values were obtained within group with Group A with NPRS mean difference 1.3, p value 0.02, ROM mean difference 1.8, p value 0.22, USG mean difference 0.8, p value 0.003, FAAM mean difference 15, p value 0.03

Table 2:

The mean values were obtained within group with Group B with NPRS mean difference 2.1, p value 0.0001, ROM mean difference 2.8, p value 0.008, USG mean difference 0.8, p value 0.14, FAAM mean difference 21.7, p value 0.0004

Table 3:

© ICAS 2022

Comparison between groups with NPRS p value 0.26, ROM p value 0.14, USG p value 0.44, FAAM p value 0.63

VI. DISCUSSION

The results obtained from the analysis states that the effects of mobilization at various joints helps in reduction of pain and inflammation in plantar fascia in subjects with Pes cavus deformity. Statistical significance was evaluated using paired 't' test within groups. This study includes outcome measures like Numerical Pain Rating Scale (NPRS) for measuring pain intensity, goniometer for ankle dorsiflexion range of motion (ROM), Musculoskletal ultrasonogram (USG) for measuring the fascia thickness, and Foot and ankle ability measure (FAAM) questionnaire for measuring the functional activities. Pain intensity in Group B has shown greater improvement when compared with Group A, this may be due to excess weight bearing at the MTP level in later phase of Pes Cavus, leading to tenderness and inflammation even at the insertion level of fascia.

Travis et al (2021) stated that pes cavus is a deformity that is typically characterized by mostly plantar flexion of first ray. Orthotic management to first ray relieves maximum tension.[8] Previous studies have found an association between dorsiflexion ROM and Plantar fasciitis. Cleland et al (2009) examined the effect of mobilization on pain and functional outcomes in patients with plantar fasciitis and found that patients treated with joint mobilization had a positive outcome; however, due to the abundance of techniques and joints involved, they couldn't determine which technique was superior and which joint was the most relevant. In this study both groups have shown improvement at a very minimal range which is not significantly driven; hence it has been assumed that mobilizations at various level had contribution in improving the range but not on a vast scale.

USG is a non-invasive, inexpensive, easy to perform technique , which makes it an ideal imaging modality for the diagnosis of plantar fasciitis, with good sensitivity and specificity. Olga kiritsi et al (2010) stated that thickening of the plantar fascia more than 4mm is a well-established sonographic criterion for the diagnosis of plantar fasciitis.

Cenk et al (2018) stated that MRI are the changes in perifascial soft tissue edema and fascia signal intensity , which when treated usually regress and patients tend to have functional recovery. The qualitative assessment of the fascia has shown improvement by reducing the fascia thickness by the end of the treatment protocol in both groups.[9] Activities of daily living was measured using the FAAM questionnaire among which the subjects has not shown much significance. This could be because of continous weight bearing and shorter during of intervention. Conventional intervention like TENS could also be a contributing factor along with mobilization.

In this study the subjects underwent the protocol for about 2 weeks and by second week of intervention the subjects felt comfortable during walking or standing and also subjects felt pain reduction. Last second or third sittings of mobilization; subjects were resulted in lowering of medial foot to plantigrade in standing and minimal first toe weight bearing during gait and also resulted in improvement of dorsiflexion of ankle joint.

© ICAS 2022

So subjects from both groups got overall result of improvement in the standing posture and during gait. The mobilization of the talonavicular and first metatarsal phalangeal joint improved the joint mobility. Therefore, results showed a significant improvement in the ADL activity and improved foot comfort.

VII. CONCLUSION

It is concluded that there was a significant improvement in mobilizing the first MTP joint on pes cavus subjects with plantar fasciitis which resulted in reducing pain, inflammation, improving ROM and ADL when compared to talonavicular joint mobilization.

VIII. LIMITATIONS & RECOMMENDATIONS

- Sample size is small
- Footwear modification can be added to rule out its efficiency
- There wasn't reduction in arch followed by intervention
- Intervention period was limited
- Follow up can be done

IX. REFERENCES

1. Fernández-Seguín LM, Heredia-Rizo AM, Díaz-Mancha JA, González- García P, Ramos-Ortega J, Munuera-Martínez PV. Immediate and short- term radiological changes after combining static stretching and transcutaneous electrical stimulation in adults with cavus foot: A randomized controlled trial. Medicine. 2019 Nov;98(46).
2. Inamdar P, Fantani D, Rajiwate F, Shaikh B DB, Shaikh S, Ranka B DS. Prevalence of flat foot and high arched foot in nor-mal working individuals using footprint method. Int. J. Physiother. Res. 2018;6(3):2754-8.
3. Chevutschi A, D'houwt J, Pardessus V, Thevenon A. Immediate effects of talocrural and subtalar joint mobilization on balance in the elderly. Physiotherapy Research International. 2015 Mar;20(1):1-8.
4. Zeidan H, Kawagoe M, Kajiwara Y, Harada K, Nishida Y, Yamada K, Kawabe R, Yokota J, Yamashiro C, Odake Y, Takeda M. The shape of the transverse arch in high heels while standing. Plos one. 2020 Jun 8;15(6):e0233958.
5. Chen WM, Lee SJ, Lee PV. Plantar pressure relief under the metatarsal heads–Therapeutic insole design using three-dimensional finite element model of the foot. Journal of biomechanics. 2015 Feb 26;48(4):659-65.
6. Luo G, Houston VL, Garbarini MA, Beattie AC, Thongpop C. Finite element analysis of heel pad with insoles. Journal of biomechanics. 2011 May 17;44(8):1559-65.
7. Eslami M, Tanaka C, Hinse S, Anbarian M, Allard P. Acute effect of orthoses on foot orientation and perceived comfort in individuals with pes cavus during standing. The Foot. 2009 Mar 1;19(1):1-6.
8. Seaman TJ, Ball TA. Pes Cavus. StatPearls [Internet]. 2020 Aug 11.

© ICAS 2022

9. Ermutlu C, Aksakal M, Gümüştaş A, Özkaya G, Kovalak E, Özkan Y. Thickness of plantar fascia is not predictive of functional outcome in plantar fasciitis treatment. Acta orthopaedica et traumatologica turcica. 2018 Nov 1;52(6):442-6.
10. D'Silva C, Metgud S, Heggannavar A. Comparative Effect of Mobilization, Low Dye Taping and Faradic Foot Bath in Subjects with Flat Foot – A Randomised Clinical Trial. *IOSR J Sport Phys Educ*. 2017. doi:10.9790/6737-04035560
11. Stino AM, Atway S, Anthony M, Kline D, Kissel JT. Foot measures in patients with pes cavus with and without charcot–marie–tooth disease: A pilot study. *Muscle and Nerve*. 2019. doi:10.1002/mus.26309
12. Rubella DH, Leo Aseer PA, Dev B, Jambu N. Sonographic evaluation of plantar fascia following low-level laser therapy in plantar fasciitis. *Int J Physiother*. 2019. doi:10.15621/ijphy/2019/v6i2/181911
13.RAJALAXMI, V., G. MOHANKUMAR, and K. RAMANATHAN. "EFFECTIVENESS OF PLANTAR FASCIA STRETCHING Vs CONTRAST BATH COMBINED WITH ULTRASOUND IN PLANTAR FASCIITIS." *BEST: International Journal of Humanities, Arts, Medicine and Sciences (BEST: IJHAMS)* 4 (2016): 71-78. BEST : International Journal of Humanities , Arts, Medicine and Sciences(BEST : IJHAMS)

© ICAS 2022